

AMELIORATIVE EFFECTS OF *ANNONA MURICATA* LEAF EXTRACT ON POLYCYSTIC OVARIAN SYNDROME IN FEMALE MICE

*¹O. E. ADELEYE, M. P.¹, IGBEKOYI, ¹O. E. ADEYANKINNU,
²O. A. ADEKOYA, ³A. I. ADELEYE, ⁴O. A. AYEGBOYIN

1. Department of Veterinary Physiology and Biochemistry, Federal University of Agriculture, Abeokuta, Nigeria.
 2. Department of Veterinary Pharmacology and Toxicology, Federal University of Agriculture, Abeokuta, Nigeria.
 3. Veterinary Teaching Hospital, Federal University of Agriculture, Abeokuta, Nigeria.
 4. Department of Physiology, Faculty of Basic Medical Sciences, University of Ibadan, Ibadan; Department of Psychology, University of Portsmouth, United Kingdom.
- *Corresponding Author: adeleyeoe@funaab.edu.ng, Tel: +2348037551972

ABSTRACT

Polycystic Ovary Syndrome (PCOS) is a prevalent endocrine disorder affecting women of reproductive age, characterized by hyperandrogenism, oligo-ovulation, and polycystic ovaries. The disorder is linked to increased risks of cardiovascular disease and non-insulin-dependent diabetes mellitus. This study evaluated the ameliorative effects of *Annona muricata* (Soursop) leaf extract on letrozole-induced PCOS in female mice, focusing on ovarian weight, histopathology and metabolic parameters. Twelve pubertal mice were assigned to test and control groups, with the test groups receiving letrozole (2.5 mg/kg, *per os*) and *Annona muricata* leaf extract (AMLE) 125 & 250 mg/kg by oral gavage; control groups received letrozole (2.5 mg/kg, *per os*) only; all were given standard feed and water *ad libitum*. Fasting blood glucose was measured using a glucometer, while body, ovarian and parametrial fat weights were measured using a sensitive balance. AMLE did not significantly affect ovarian weight or relative body weight gain. Fasting blood glucose levels were significantly higher in the test group compared to controls, suggesting a potential discrepancy in the anti-diabetic properties. Mild follicular degeneration in the LETAM group was observed, suggesting partial preservation of ovarian architecture and a potential protective effect of the extract. *Annona muricata* leaf extract may offer therapeutic benefits in mitigating ovarian damage associated with PCOS but its impact on glucose metabolism requires further investigation. There is the need for deeper exploration into dosage, treatment duration and metabolic interactions to fully understand the clinical potentials of the extract.

Keywords: Polycystic Ovary Syndrome; Soursop; letrozole; ovarian histology; blood glucose; reproductive health; endocrine disorder

INTRODUCTION

Polycystic ovary syndrome (PCOS) is the most common endocrine disorder in reproductive-aged women, with prevalence be-

tween 5% and 15%, depending on the diagnostic criteria applied (Ehrmann, 2005, Lauritsen *et al.*, 2014.). Most of the symptoms of PCOS are caused by higher-than-normal lev-

els of hormones called androgens. PCOS was first described by Stein and Leventhal as a syndrome of oligo-amenorrhea and polycystic ovaries that was variably accompanied by hirsutism, acne, and obesity (Azziz *et al.*, 2016).

The exact cause of polycystic ovaries and the related syndrome remains unclear; however, the diverse clinical manifestations of PCOS indicate that it is unlikely to stem from a single origin. Instead, it appears to result from complex molecular interactions among genetic, environmental and hormonal influences, which disrupt key regulatory pathways involved in ovarian function, steroid hormone production, insulin signaling and other physiological processes (Parker, 2025). Central to this dysfunction is a significant hormonal imbalance, characterized by heightened testosterone and progesterone activity alongside insufficient follicle-stimulating hormone (FSH) production from ovarian follicles. This disparity contributes to a cascade of clinical manifestations, including menstrual disturbances, infertility, excessive hair growth (hirsutism), obesity, and chronic inflammation. (Feinberg and Feinburg, 2004, Lebbe and Woodruff, 2013). Genetic studies have identified a link between PCOS and disordered insulin metabolism and indicate that the syndrome may be the presentation of a complex genetic trait disorder (Franks *et al.*, 2001).

The features of obesity, hyperinsulinemia and hyperandrogenaemia which are commonly seen in PCOS are also known to be factors which confer an increased risk of cardiovascular disease and non-insulin dependent diabetes mellitus (Rajkowska *et al.*, 2000). So far, the main aetiology of PCOS is still unknown and this is complicated by

the fact that PCOS is a complex genetic disease and has heterogeneous presentations.

Animal models of PCOS may help to better understand the development of PCOS-related pathologies. They may contribute to knowledge about the long-term health consequences of PCOS. An ideal animal model should replicate the most common clinical features of PCOS, which are the reproductive and metabolic abnormalities, such as: hyperandrogenemia, cystic ovaries, increase visceral mass. Most of these models are based on hyperandrogenism induced pre- or postnatally or during adulthood, because it is generally agreed that elevated androgens are the main culprit of PCOS.

Pubertally induced hyperandrogenism in non-human primates and sheep has resulted in the most suitable animal model, displaying many of the characteristics of PCOS, such as cystic ovaries, enhanced androgen production by theca cells, increased visceral fat mass, and insulin resistance (Eisner *et al.*, 2000; Abbott *et al.*, 2009; King *et al.*, 2007; Padmanabhan *et al.*, 2010; Hogg *et al.*, 2012). Yet, these models have the disadvantage that they are quite expensive and have a relatively long reproductive lifespan and gestational cycle. Consequently, many researchers, use rodents as a model of PCOS, since rodents have the advantage of being affordable, having a shorter reproductive lifespan, easier handling and having stable genetic backgrounds (Shi & Vine, 2012; Walter *et al.*, 2012).

PCOS is the leading cause of female anovulatory infertility and is estimated to affect more than 100 million women worldwide (Abbott *et al.*, 2008, Shi & Vine, 2012, Vos *et al.*, 2012). Despite the primary diagnostic

symptoms being most closely related to ovarian malfunction (Fauser *et al.*, 2012), there is evidence that changes in the brain play a significant role in the pathogenesis of the syndrome (Moore *et al.*, 2013, 2015, Osuka *et al.*, 2018, Walters *et al.*, 2018, McCartney & Campbell, 2020).

In normal conditions, the pulsatile secretion of gonadotrophin-releasing hormone (GnRH) from cells in the brain drives the pulsatile release of luteinizing hormone (LH) from the pituitary gland (Herbison, 2006). Pituitary LH travels through the circulatory system to control ovarian function and steroid hormone release. Steroid hormones then, in turn, travel back to the brain to suppress the release of GnRH/LH in a negative feedback loop. However, PCOS patients exhibit an impaired ability for steroid hormones to reduce pulsatile GnRH/LH secretion (Coyle *et al.*, 2019, Chhabra *et al.*, 2005, Yoo *et al.*, 2006). Consequently, rapid GnRH/LH pulse secretion leads to the symptoms of ovarian hyperandrogenemia (high secretion of the male hormone testosterone) and ovulatory failure.

It was hypothesized that impaired steroid hormone feedback occurs due to an increase in reactive oxygen species (ROS) within the body systems, which then leads to the symptoms of PCOS and that potent antioxidants in medicinal plants can ameliorate the PCOS symptoms.

Annona muricata, a traditional medicinal plant was investigated and showed that the phytochemical constituents and the bioactive compounds possess the medicinal properties which make them to be a potential species in the family of Annonaceae (Abdu, 2018). Research works done on this plant reveals its beneficial aspect in the field of pharmacy. *Annona muricata*, commonly

known as soursop, graviola, guanabana, paw-paw and sirsak, ebo or apekan in Yoruba, is a member of the Annonaceae family comprising approximately 130 genera and 2300 species (Mishra *et al.*, 2013, Moghadamtousi *et al.*, 2015). *Annona muricata* is native to the warmest tropical areas in South and North America and is now widely distributed throughout tropical and subtropical parts of the world, including India, Malaysia and Nigeria (Adewole and Caxton-Martins, 2006). The aerial parts of graviola have several functions: the fruits have been widely used as food confectionaries, while several preparations, especially decoctions of the bark, fruits, leaves, pericarp, seeds, and roots, have been extensively used in traditional medicine to treat multiple ailments including cancers by local communities in tropical Africa and South America (Rady *et al.*, 2018). Several studies by different researchers demonstrated that the leaves of *Annona muricata* had antioxidant and anti-diabetic (Chowdhury *et al.*, 2021), anti-cancer (Jaramillo *et al.*, 2000; Tormo *et al.*, 2003; Prasad *et al.*, 2019), anti-bacterial (Takahashi *et al.*, 2006), anti-fungal (Heinrich *et al.*, 1992), anti-malarial, anti-mutagenic, emetic and anti-convulsant activities in animals (Opara *et al.*, 2021). It is also believed to be a digestive stimulant, anti-viral (Balderrama-Carmona *et al.*, 2020), cardio tonic, antiparasitic (Coria-Téllez *et al.*, 2018), analgesic, antirheumatic and astringent (Dos Santos and Santana, 2000).

PCOS is the leading cause of female anovulatory infertility and is estimated to affect more than 100 million women worldwide (Abbott *et al.*, 2008, Shi & Vine, 2012, Vos *et al.*, 2012). Despite the primary diagnostic symptoms being most closely related to ovarian malfunction (Fauser *et al.*, 2012), there is evidence that changes in the brain

play a significant role in the pathogenesis of the syndrome (Osuka, 2018, Walters *et al.*, 2018, McCartney & Campbell, 2020). Also, impaired steroid hormone feedback occurs due to an increase in reactive oxygen species (ROS) within the body systems and there is little or no documented literature on the ameliorative effects of *Annona muricata* extract on PCOS symptoms. This research was therefore conducted to determine the ameliorative potentials of *Annona muricata* leaf ethanol extract on letrozole-induced PCOS symptoms in mice.

MATERIALS AND METHODS

PLANT COLLECTION

Fresh *Annona muricata* leaves were plucked from trees around FUNAAB environs, Abeokuta.

Plant extraction

The leaves collected were rinsed with clean water to remove all forms of debris. They were also air dried for two weeks under shade to prevent the heat of the sun from tampering with the quercetin content. After drying completely, the leaves were grinded to fine powder and weighed. The fine powder of the leaves weighing 267 g (total weight got from the collected and dried leaves) was soaked in 1000 ml of 100% ethanol for 72 hours at room temperature (Khaki *et al.*, 2009). This mixture was then filtered into a conical flask using a Whatman's filter paper handkerchief. The filtrate was then concentrated using a rotary evaporator to obtain a gel-like extract.

Reconstitution of plant extract

A solution of 504 mg/ml was prepared by dissolving 5.04 g (total extract required for the study) of the plant extract (derived from the plant extraction) in 10 mls of tween-20.

Tween-20 also known as polysorbate 20 is a non-ionic surfactant and emulsifier derived from sorbitol.

Study location

This study was carried out at the animal house and the Veterinary Physiology laboratory, College of Veterinary Medicine (COLVET), Federal University of Agriculture, Abeokuta.

Experimental animals

12 pubertal mice weighing between 14 g and 20 g were obtained from the Animal house, Department of Pure and Applied Zoology, College of Biological sciences, FUNAAB. They were kept under normal conditions throughout the period of experiment. All mice were fed standard pelleted mice feed (Top feed®) with unrestricted access to feed and water. They were also allowed to acclimatize for one week prior the commencement of the experiment.

PCOS models

PCOS was induced in pubertal female mice via oral administration of letrozole (2.5 mg/kg) for a duration of 21 days.

STUDY DESIGN

Animal groups

The mice were assigned into three major groups:

- CON (negative control group) - distilled water
- LET (positive control group) - letrozole (2.5 mg/kg by oral gavage)
- LETAM - letrozole 2.5 mg/kg + 250 mg/kg *Annona muricata* extract (by oral gavage)

BODY WEIGHT EVALUATION

The body weights of the mice were taken daily using a digital weighing scale (CAMRY® scale) throughout the period of the experiment. After the experiment, per-

centage weight gain was calculated using the formula:

$$\text{Relative body weight gain} = \frac{\text{Initial weight} - \text{Final weight}}{\text{Final weight}} \times 100$$

The starting weight was subtracted from the end weight and the difference was divided by the end weight and finally multiplied by 100 to get the relative body weight gain.

Letrozole treatment and administration of plant extract

Letrozole was administered orally using an oral cannula with a dosage of 2.5 mg/kg in the morning and then 250 mg/kg of the aqueous extract of *Annona muricata* was given orally in the afternoon. The mice in the positive test groups were given letrozole with a dosage of 2.5 mg/kg while the ones in negative test groups were given feed and water. The treatment duration was 21 days.

Measurement of fasting blood glucose level

The mice were fasted 17 hours before blood sample collection, but were given water. The blood glucose level for individual mice was measured using ACCU-CHEK® glucometer (Plate 1 & 2). Blood collected by cutting the tip of the mice tail was placed on the test strip and the values were read after 5 seconds to determine the fasting blood glucose level. This process utilizes enzymes which are specialized proteins capable of catalyzing chemical reaction. The test strips used contain enzymes that react with glucose in the blood. Occasionally, this chemical reaction results in a colour change which the glucometer detects and converts into a glucose concentration measurement (mg/dL).



Plate 1: Blood collection and glucose determination

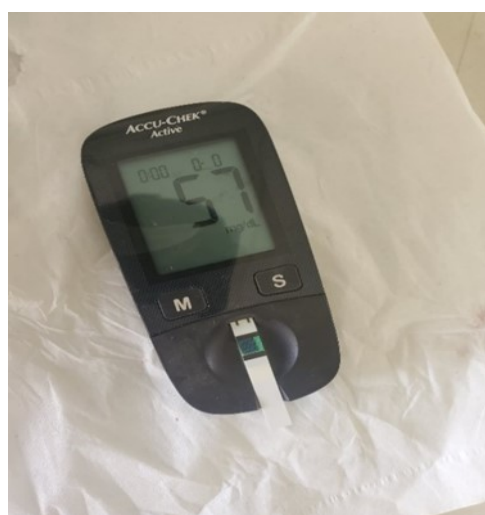

Plate 2: ACCU-CHEK® glucometer used for fasting blood glucose

Determination of ovarian and parametrial fat weight

The mice in the test groups and the control groups were sacrificed by cervical disloca-

tion; the ovaries and the parametrial fat were harvested. The weights were then measured, using a sensitive weighing balance.

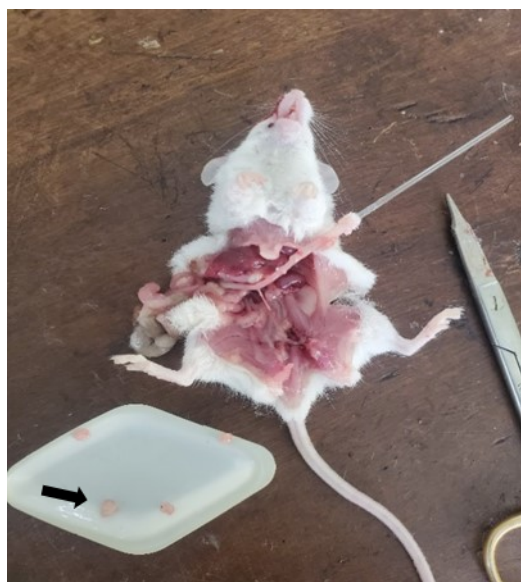

Plate 3: Harvesting of ovaries (arrow)

Data analysis

The data obtained were statistically analyzed using SPSS 28 (IBM) program according to Glantz method. Notable differences among groups were also determined by one-way analysis of variance (ANOVA). Post hoc test was done using Turkey's test to compare significance at $P \leq 0.05$.

RESULTS

Clinical changes

The clinical changes seen after a period of 21 days from the three (3) female mice and the control three (3) female mice used for this research were recorded and analyzed daily.

Ovarian weight (Fig 1), fasting blood glucose (Fig 2), the relative body weight gain (Fig 3), parametrial fat weight (Fig 4) were also recorded and analyzed.

Ovarian weight

There was no significant increase in the ovarian weight of test groups (LETAM) compared to LET (Positive control) ranging from 0.021 ± 0.002 to 0.022 ± 0.0003 g (Figure 1)

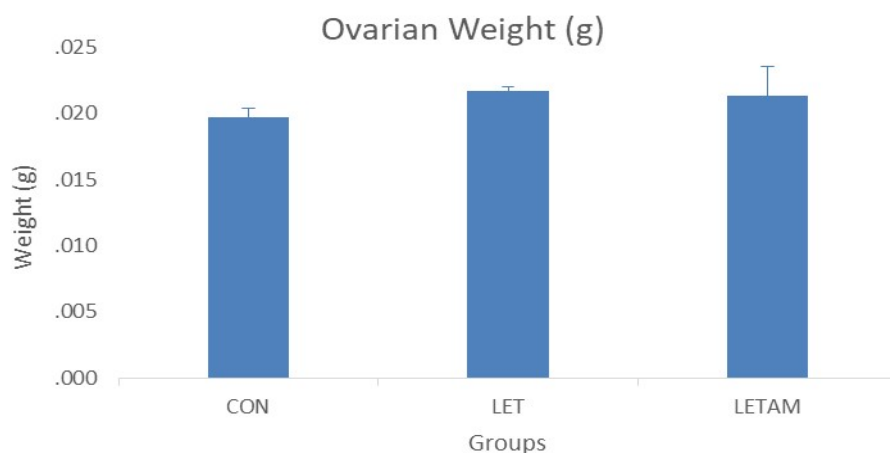


Figure 1: Ovarian weight of the female mice in test and control groups after treatment for a period of 21 days. Columns represent mean \pm SEM, n=3, *P \leq 0.05 =no significant difference from LET. CON = Feed and water only, LET = mice given 2.5 mg/kg of letrozole, LETAM = mice given 2.5 mg/kg of letrozole + 250 mg/kg of *Annona muricata* leaf extract daily.

Fasting blood glucose

There was significant increase in the fasting blood glucose of the test group LETAM compared to LET. The test group

(LETAM) had the highest fasting blood glucose level (140.0 \pm 7.7) at the end of 21 days while LET had the lowest of 59.0 \pm 0.58 (Figure 2).

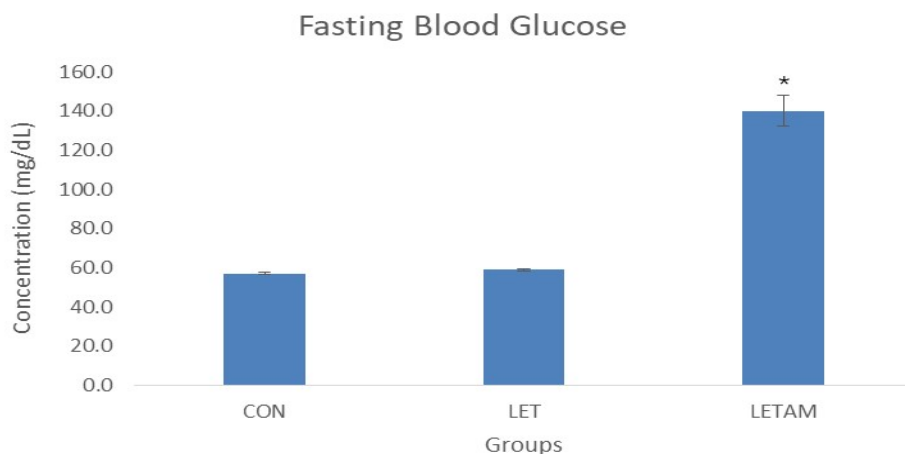


Figure 2: Fasting blood glucose level of mice in test and control groups after treatment for a period of 21 days. Columns represent mean \pm SEM, n=3, *P \leq 0.05 = significant difference from LET group. CON = Feed and water only, LET = mice given 2.5 mg/kg of letrozole, LETAM = mice given 2.5 mg/kg of letrozole + 250 mg/kg of *Annona muricata* leaf extract daily.

Relative body weight gain

There was no significant increase in the relative weight gain of test groups LETAM

compared to LET (Positive control), ranging from 8.5 ± 0.28 to 8.8 ± 0.06 g with the lowest of 8.5 ± 0.28 g from LETAM (Figure 3).

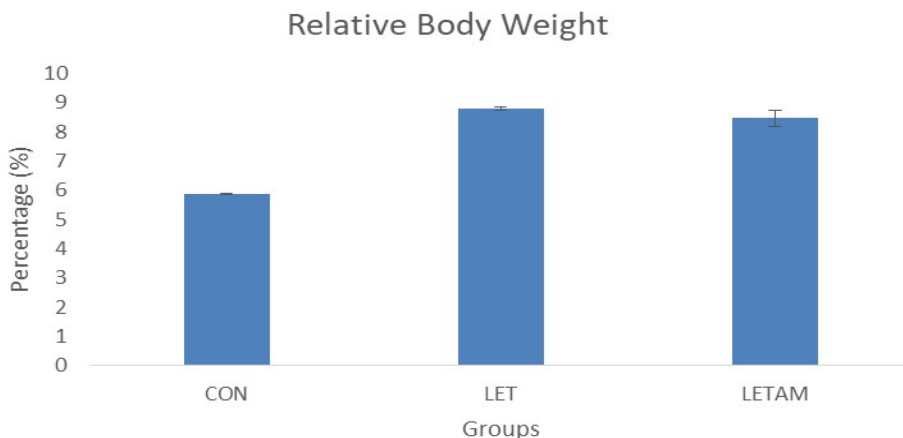


Figure 3: Relative body weight gain of the female mice in test and control groups after treatment for a period of 21 days. Columns represent mean \pm SEM, n=3, *P \leq 0.05 =no significant difference from LET. CON = Feed and water only, LET = mice given 2.5 mg/kg of letrozole, LETAM = mice given 2.5 mg/kg of letrozole + 250 mg/kg of *Annona muricata* leaf extract daily.

PARAMETRIAL FAT WEIGHT

There was no significant increase in the parametrial fat weight of test groups LETAM compared to LET (Positive control), rang-

ing from 0.016 ± 0.003 to 0.023 ± 0.0006 g with the lowest of 0.016 ± 0.00 g from LETAM (Figure 4).

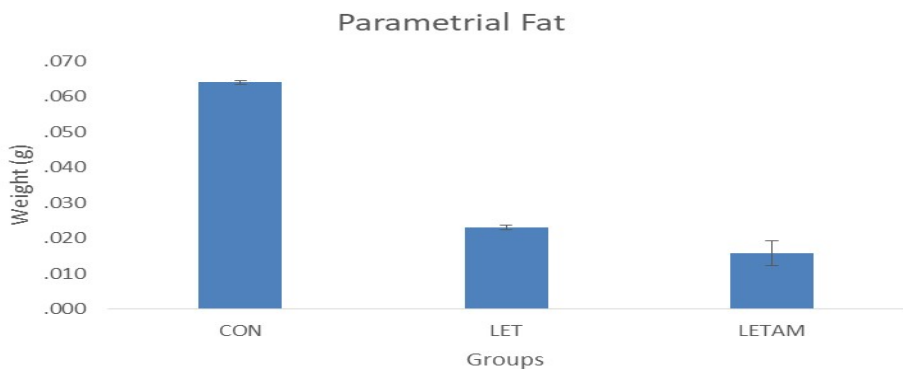


Figure 4: Parametrial fat weight of the female mice in test and control groups after treatment for a period of 21 days. Columns represent mean \pm SEM, n=3, P \leq 0.05 = no significant difference from LET. CON = Feed and water only, LET = mice given 2.5 mg/kg of letrozole, LETAM = mice given 2.5 mg/kg of letrozole + 250 mg/kg of *Annona muricata* leaf extract daily.

Histological slide of the negative control group (CON): All sections were stained with H&E. Original magnification: 400x, scale bar: 200 μ m. Developmental stages of follicles (arrow) in the negative control (CON) group.

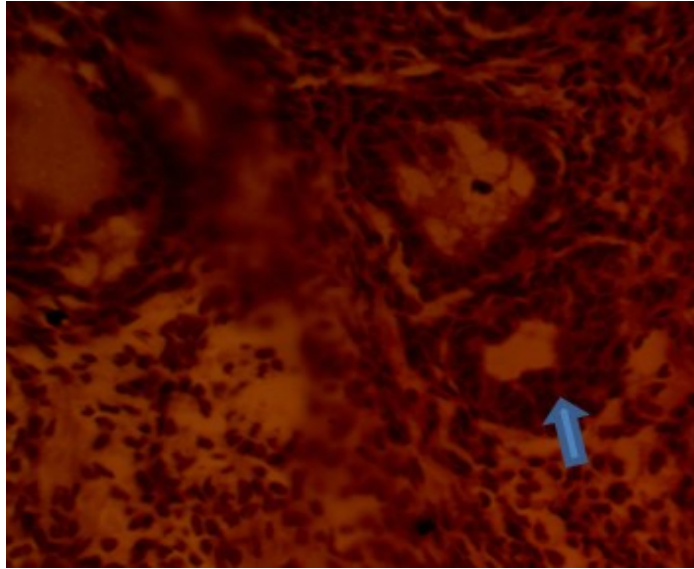


Plate 4: Effects of *Annona muricata* ethanol extract on the ovaries of letrozole-induced PCOS mice.

Histological slide of the positive control group (LET): All sections were stained with H&E. Original magnification: 400x, scale bar: 200 μ m. Necrotized follicles (arrow) identified in the positive control (LET) group.

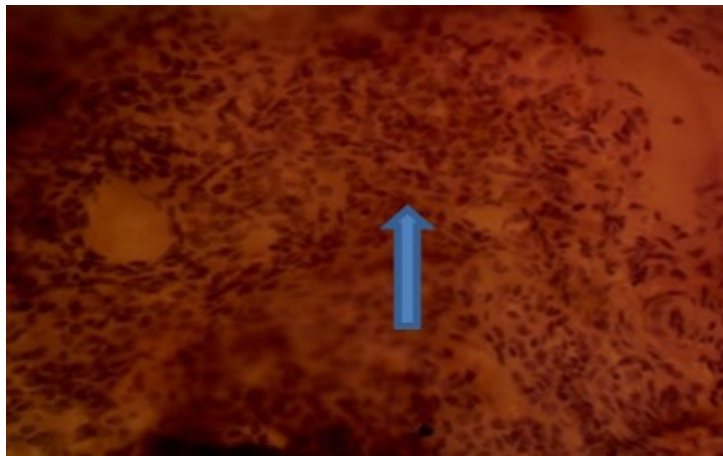


Plate 5: Effects of *Annona muricata* ethanol extract on the ovaries of letrozole-induced PCOS mice.

Histological slide of the letrozole + *Annona muricata* group (LETAM): All sections were stained with H&E. Original magnifica-

tion: 400x, scale bar: 200 μ m. Mild degeneration of follicles (arrow) identified in the test (LETAM) group.

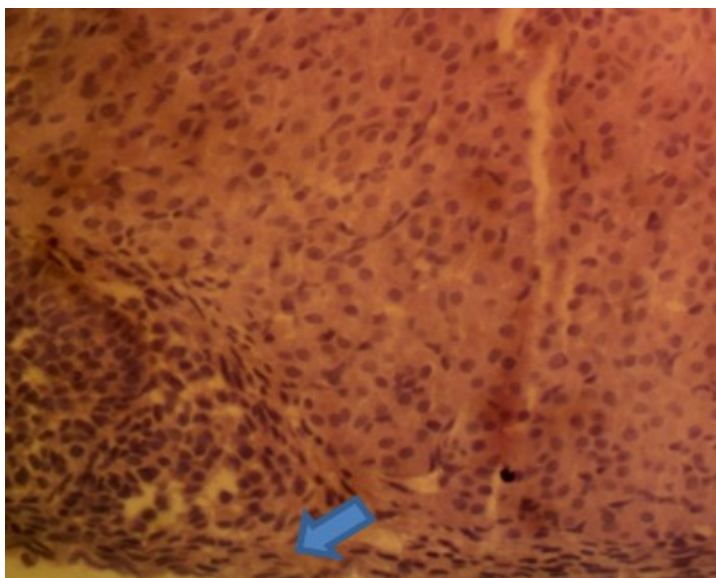


Plate 6: Effects of *Annona muricata* ethanol extract on the ovaries of letrozole-induced PCOS mice

DISCUSSION

Polycystic ovary syndrome (PCOS) is a highly prevalent disorder, representing the single most common endocrine–metabolic disorder in reproductive-aged women. It is a clinical syndrome, that is, a collection of signs and symptoms, including clinical or biochemical hyperandrogenism, oligoanovulation, and polycystic ovarian morphology (Azziz *et al.*, 2016).

This study explored the potential ameliorative effects of *Annona muricata* leaf extract on polycystic ovarian syndrome (PCOS) in female mice, with a focus on reproductive and metabolic parameters.

The analysis of ovarian weight indicated no significant difference between the test

group (LETAM) and the positive control group (LET). This result has suggested that while *Annona muricata* extract might not significantly reduce ovarian weight, it does not exacerbate it either. Previous studies by Mansour *et al.*, (2022), Yuanyuan *et al.* (2025) and Namli *et al.* (2023) highlight that ovarian weight can be a variable factor influenced by multiple aspects of PCOS pathology, which could explain the lack of significant change.

The fasting blood glucose levels showed a significant increase in the test group (LETAM) compared to the positive control (LET), with the highest levels recorded in the test group at the end of the 21-day period. The LETAM group's elevated glucose levels were unexpected; especially given prior research suggesting *Annona muricata* has anti-diabetic properties as documented by Ade-

leye *et al.*, (2019), Ramírez-Rodríguez *et al.*, (2021) and Ma *et al.*, (2022), who reported the anti-diabetic properties of *Annona muricata*. This result may indicate a dose-dependent effect where the administered quantity of extract was insufficient or counterproductive; or a possible interaction between the extract and letrozole that disrupts glucose regulation. It may also be due to the extract's benefits may be limited to reproductive or histological improvements and not metabolic control. This implies that while *Annona muricata* may offer protective effects on ovarian morphology, its impact on glucose metabolism in PCOS models is questionable. The increase in glucose levels also suggests that, under the conditions of this experiment, the extract may not exert the expected glycemic control and could potentially exacerbate hyperglycemia in PCOS models.

There was no significant increase in the relative body weight gain of the test group (LETAM) compared to the positive control (LET). This aligns with the findings of Mishra *et al.*, (2013) and Kumar *et al.* (2021), who observed that *Annona muricata* does not significantly affect body weight in animal models. The stabilization of body weight could be beneficial in managing PCOS-related obesity without causing adverse weight gain.

The parametrial fat weight analysis indicated no significant difference between the test group (LETAM) and the positive control (LET). This result suggests that the extract might help in managing fat accumulation associated with PCOS, supporting the findings of Abbott *et al.*, (2009) and Walters *et al.*, (2018), who emphasized the role of metabolic regulation in PCOS management. Comparing these results with other studies,

there are both consistencies and contradictions. However, the increase in fasting blood glucose levels contradicts findings from previous research on the anti-diabetic properties of the plant by Adeleye *et al.*, 2019.

The lack of significant change in ovarian weight and body weight gain aligns with the multifactorial nature of PCOS, as described by Azziz *et al.*, (2016). The results suggest that while *Annona muricata* extract shows potential in managing certain symptoms of PCOS, its effects on glucose metabolism need further investigation.

Despite the metabolic concerns, the lack of significant changes in ovarian weight, body weight gain, and parametrial fat suggests that the extract does not worsen PCOS-related obesity or adiposity. This aligns with findings from Mishra *et al.* (2013) and Kumar *et al.* (2021), who reported neutral effects of *Annona muricata* on body weight.

Microscopic analysis of the ovarian tissue slides showed clear morphological variations across the experimental groups, reflecting differences in follicular integrity and degrees of degeneration. In the negative control group (CON), ovarian tissue exhibited typical follicular development, aligning with the expected physiological condition of weaned mice undergoing natural ovarian maturation. Conversely, the positive control group (LET) exhibited marked necrosis of ovarian follicles, validating the effective induction of polycystic ovarian syndrome (PCOS) and underscoring the detrimental impact of letrozole on ovarian structure. These observations are consistent with the findings of Wang *et al.* (2012), who documented a decrease in granulosa cell layers accompanied by mesenchymal cell hyperplasia in PCOS-induced rats. The LETAM test group showed signs of

mild follicular degeneration, indicating that the *Annona muricata* ethanolic extract may offer protective or healing benefits against ovarian damage caused by letrozole. This limited retention of ovarian architecture suggests that the extract could hold therapeutic promise in alleviating the histopathological changes linked to PCOS.

CONCLUSION

These findings suggest that *Annona muricata* may help counteract letrozole-induced ovarian damage. *Annona muricata* may also have influence on glucose metabolism which may be dose-dependent or model-specific and warrants further investigation. *Annona muricata* leaf extract demonstrates potential as a supportive agent in PCOS management, especially in preserving ovarian histology, but its metabolic implications must be carefully evaluated in future studies.

LIMITATION

The concentration of leaves extracted in ethanol should be investigated to establish optimum ratio.

REFERENCES

Abbott, D. H., Barnett, D. K., Bruns, C. M., D. A. Dumesic 2009. Androgen excess fetal programming of female reproduction: A developmental aetiology for polycystic ovary syndrome? *Human Reproduction Update* 11: 357–374. <https://doi.org/10.1093/humupd/dmi013>.

Abbott, D. H., Tarantal, A. F., D. A. Dumesic 2009. Fetal, infant, adolescent and adult phenotypes of polycystic ovary syndrome in prenatally androgenized female rhesus monkeys. *American Journal of Primatology* 71(9): 776–784.

Abbott, D. H., Zhou, R., Bird, I. M., Dumesic, D. A., A. J. Conley 2008. Fetal programming of adrenal androgen excess: Lessons from a nonhuman primate model of polycystic ovary syndrome. In *KARGER eBooks* (/pp. 145–158). <https://doi.org/10.1159/000134831>

Abdu, S. B. 2018. *Annona muricata* (Graviola): A Review of Its Traditional Uses and Pharmacological Activities. *International Journal of Life Sciences Research* 2348-3148 6(1): 50-57

Adeleye, O. E., Aboajah, N. A., Adeleye, A. I., Sogebi, E. A. O., Mshelbwala, F. M., Adetomiwa, A. S., J. O. Olukunle 2019. *Annona muricata* Linn. ethanolic leaf extract ameliorates reproductive complications in streptozotocin-induced diabetic Wistar rats. *Journal of Natural Sciences Engineering and Technology* 18(1&2): 166–175.

Adewole, S. O., E. A. Caxton-Martins 2006. Morphological changes and hypoglycemic effects of *Annona muricata* Linn. leaf aqueous extract on pancreatic B-cells of streptozotocin-treated diabetic rats. *African Journal of Biomedical Research* 9: 173–187.

Azziz, R., Carmina, E., Dewailly, D., Diamanti-Kandarakis, E., Escobar-Morreale, H. F., Futterweit, W., S. F. Witchel 2016. Criteria for defining polycystic ovary syndrome as a predominantly hyperandrogenic syndrome: An Androgen Excess Society guideline. *Journal of Clinical Endocrinology & Metabolism* 91(11): 4237–4245.

Balderrama-Carmona, A. P., Silva-Beltrán, N. P., Gálvez-Ruiz, J.-C., Ruiz-Cruz, S., Chaidez-Quiroz, C., E. F. Morán-Palacio 2020. Antiviral, antioxidant, and antihemolytic effect of *Annona muricata* L.

- leaves extracts. *Plants* 9(12): 1650. <https://doi.org/10.3390/plants9121650>.
- Chhabra, S., McCartney, C. R., Yoo, R. Y., Eagleson, C. A., Chang, R. J., & J. C. Marshall** 2005. Progesterone inhibition of the hypothalamic gonadotropin-releasing hormone pulse generator: Evidence for varied effects in hyperandrogenemic adolescent girls. *Journal of Clinical Endocrinology & Metabolism* 90(5): 2810–2815.
- Chowdhury, S. S., Tareq, A. M., Tareq, S. M., Farhad, S., M. A. Sayeed** 2021. Screening of antidiabetic and antioxidant potential along with phytochemicals of *Annona* genus: A review. *Future Journal of Pharmaceutical Sciences* 7: 1–10.
- Coria-Téllez, A. V., Montalvo-González, E., Yahia, E. M., E. N. Obledo-Vázquez** 2018. *Annona muricata*: A comprehensive review on its traditional medicinal uses, phytochemicals, pharmacological activities, mechanisms of action and toxicity. *Arabian Journal of Chemistry* 11(5): 662–691.
- Dos Santos, R. B., D. G. Santana** 2000. Medicinal plants used in traditional medicine in Brazil: *Annona muricata* as astringent and antirheumatic. *Revista Brasileira de Farmacognosia*, 10(1), 31–35.
- Eisner, J. R., Dumesic, D. A., Kemnitz, J. W., D. H. Abbott** 2000. Timing of prenatal androgen excess determines differential impairment in insulin secretion and action in adult female rhesus monkeys. *Journal of Clinical Endocrinology & Metabolism*, 85(3), 1206–1210.
- Fausser, B. C. J. M., Tarlatzis, B. C., Rebar, R. W., Legro, R. S., Balen, A. H., Lobo, R. A., K. T. Barnhart** 2012. Consensus on women's health aspects of polycystic ovary syndrome (PCOS): The Amsterdam ESHRE/ASRM-Sponsored 3rd PCOS Consensus Workshop Group. *Fertility and Sterility*, 97(1), 28–38.
- Franks, S., Gharani, N., & M. I. McCarthy** (2001). Candidate genes in polycystic ovary syndrome. *Human Reproduction Update* 7 (4), 405–410.
- Heinrich, M., Robles, M., West, J. E., & S. Gibbons** 1992. Ethnopharmacology of *Annona muricata*: Antifungal and antibacterial properties. *Journal of Ethnopharmacology* 36(2): 101–108.
- Herbison, A. E.** 2006. Physiology of the gonadotropin-releasing hormone neuronal network. In *Knobil and Neill's Physiology of Reproduction* (pp. 1415–1482). Elsevier.
- Hogg, K., Young, J. M., Oliver, E. M., Souza, C. J., McNeilly, A. S., & W. C. Duncan** 2012. Enhanced thecal androgen production is prenatally programmed in an ovine model of polycystic ovary syndrome. *Endocrinology* 153(1): 450–461.
- Jaramillo, M. C., Arango, G. J., Gonzalez, M. C., Robledo, S. M., & I. D. Velez** 2000. Cytotoxicity and antileishmanial activity of *Annona muricata* pericarp. *Fitoterapia* 71(1): 183–186.
- Khaki, A., Fathiazad, F., Nouri, M., Khaki, A. A., Khamenehi, H. J. & M. Hamedeh** 2009. Evaluation of androgenic activity of *Allium cepa* on spermatogenesis in the *Morphologica* 68(1): 45-51.
- King, A. J., Olivier, N. B., Mohankumar, P. S., Lee, J. S., Padmanabhan, V., G. D. Fink** 2007. Hypertension caused by prenatal

- testosterone excess in female sheep. *American Journal of Physiology-Endocrinology and Metabolism* 292(6): E1837–E1841.
- Kumar, A., Woods, K. S., Bartolucci, A. A., R. Azziz** (2021). Evaluation of *Annona muricata* leaf extract on metabolic parameters in PCOS-induced rats. *Journal of Ethnopharmacology* 273: 113–120.
- Lauritsen, M. P., Bentzen, J. G., Pinborg, A., Loft, J. L., Forman, L. L., Thuesen, A., Cohen, D. M., Hougaard, A. Nyboe Andersen** 2014. The prevalence of polycystic ovary syndrome in a normal population according to the Rotterdam criteria versus revised criteria including anti-Müllerian hormone. *Human Reproduction* 29(4): 791–801.
- Lebbe, M., T. K. Woodruff** 2013. Network interactions among hormones and their receptors in the ovary. *Endocrine Reviews* 34(5): 593–638.
- Ma, H., Li, Z., Shun, Q., Liu, H., Zhao, X., & X. Guo** 2022. The impact of *Annona muricata* leaf extract on blood glucose levels in diabetic models. *Journal of Ethnopharmacology* 282: 114563.
- Mansour, A., Hashemi Taheri, A. P., Moradi, B., Mohajeri-Tehrani, M. R., Qorbani, M., Ghorbani P., S., Sanginabadi, M., S. M. Sajjadi-Jazi** 2022. Ovarian volume, not follicle count, is independently associated with androgens in patients with polycystic ovary syndrome. *BMC Endocrine Disorders* 22(1):298. doi: 10.1186/s12902-022-01224-y.
- McCartney, C. R., R. E. Campbell** 2020. The emerging role of kisspeptin in the pathophysiology of PCOS. *Endocrine Reviews* 41(4): 531–537.
- Mishra, M., S. Chaudhury** 2013. Effect of *Annona muricata* on body weight and reproductive hormones in PCOS-induced rats. *International Journal of Pharmaceutical Sciences Review and Research* 21(2): 45–50.
- Moghadamtousi, S. Z., Rouhollahi, E., Hajrezaie, M., Karimian, H., Abdulla, M. A., H. A. Kadir** 2015. *Annona muricata* leaves accelerate wound healing in rats via involvement of Hsp70 and antioxidant defence. *International Journal of Surgery* 18: 110–117.
- Moore, A. M., Prescott, M., R. Campbell** 2013. Estradiol negative and positive feedback in a prenatal androgen-induced mouse model of polycystic ovarian syndrome. *Endocrinology* 154(2): 796–806.
- Moore, A. M., Prescott, M., Marshall, C. J., Yip, S. H., R. Campbell** 2015. Enhancement of a robust arcuate GABAergic input to gonadotropin-releasing hormone neurons in a model of polycystic ovarian syndrome. *Proceedings of the National Academy of Sciences* 112(2): 596–601.
- Namlı, K. M., Anadol, E., Kalem, Z., Sezginer, P.Y., Elmas, C., Yılmaz, C., B. Bakirarar** 2023. A rat study on the PTEN expression in ovarian tissue in PCOS and folliculogenesis. *Science Report* 13(1): 20774. doi: 10.1038/s41598-023-47809.
- Opara, E. I., G. C. Chinyere** 2021. Pharmacological evaluation of *Annona muricata* leaf extract: Antioxidant, anti-convulsant, and anti-mutagenic properties. *Journal of Ethnopharmacology* 267: 113–120.
- Osuka, S., A. Nakanishi** 2018. Pathophysiological roles of inflammation in polycystic

- ovary syndrome. *Reproductive Medicine and Biology* 17(3): 295–302.
- Padmanabhan, V.** (2009). Polycystic ovary syndrome—“A riddle wrapped in a mystery inside an enigma.” *Journal of Clinical Endocrinology & Metabolism* 94(6): 1883–1885.
- Padmanabhan, V., Veiga-Lopez, A., Abbott, D. H., Recabarren, S. E., C. Herkimer** (2010). Developmental programming: Impact of prenatal testosterone excess and postnatal weight gain on insulin sensitivity index and transfer of traits to offspring of overweight females. *Endocrinology* 151(2): 595–605.
- Prasad, S., Tyagi, A. K., B. B. Aggarwal** 2019. *Annona muricata* and cancer: A review of its therapeutic potential. *Phytotherapy Research* 33(3): 591–606.
- Rajkowska, M., Glass, M. R., Rutherford, A. J., Michelmore, K., A. H. Balen** 2000. Polycystic ovary syndrome: A risk factor for cardiovascular disease? *British Journal of Obstetrics and Gynaecology* 107(1): 11–18.
- Ramírez-Rodríguez, A. M., González-Ortiz, M., Martínez-Abundis, E., & M. A. Espinosa-Camacho** 2021. Hypoglycemic effect of *Annona muricata* leaf extract in diabetic rats. *Journal of Medicinal Food* 24(2): 123–129.
- Rady, I., Bloch, M. B., Chamcheu, J. C., Banang Mbeumi, S., Anwar, M. R., Mohamed, H., J. C. Chamcheu** 2018. Anticancer properties of Graviola (*Annona muricata*): A comprehensive mechanistic review. *Oxidative Medicine and Cellular Longevity*, 2018: 1826170.
- Shi, D., D. F. Vine** 2012. Animal models of polycystic ovary syndrome: A focused review of rodent models in relationship to clinical phenotypes and cardiometabolic risk. *Fertility and Sterility* 98(1): 185–193.
- Solorzano, C. M. B., Beller, J. M., Abshire, M. L., Collins, J. S., McCartney, C. R., J. C. Marshall** 2012. Neuroendocrine dysfunction in polycystic ovary syndrome. *Steroids* 77(4): 332–337.
- Takahashi, J. A., Pereira, C. R., Pimenta, L. P., Boaventura, M. A., L. G. Silva** 2006. Antibacterial activity of eight Brazilian Annonaceae plants. *Natural Product Research* 20(1): 21–26.
- Tormo, J. R., Royo, I., Gallardo, T., Zafra-Polo, M. C., Hernandez, P., Cortes, D., F. Pelaez** 2003. In vitro-antitumor structure activity relationships of acetogenins from *Annona muricata*. *Cancer Letters* 197(1–2): 133–139.
- Vos, M. J., Romijn, J. A., Valkenburg, O., J. S. E. Laven** (2012). PCOS: A multifactorial disorder. *European Journal of Endocrinology* 166(5): 613–618.
- Walters, K. A., Gilchrist, R. B., Ledger, W. L., Teede, H. J., Handelsman, D. J., R. E. Campbell** 2018. New perspectives on the pathogenesis of PCOS: Neuroendocrine origins. *Trends in Endocrinology and Metabolism* 29(12): 841–852.
- Wang, Y., Y. Li** 2012. Histopathological changes in PCOS-induced rats. *Journal of Reproductive Biology* 14(2): 89–95.
- Yildiz, B. O., R. Azziz** 2012. The adrenal and polycystic ovary syndrome. *Reviews in Endocrine and Metabolic Disorders* 13(3) 163–175.

Yoo, R. Y., & J. C. Marshall 2006. Hypothalamic dysfunction in PCOS. *Endocrinology* 147(2): 509–517.

Yuanyuan, C., Ningyu, S., Lu, L., Wuwen, Z., Kai, L., Yanting, L., Junlan,

H., Xiang, C., Jing, Z., Hua Y. & Y. Ping 2025. Transcriptomic analysis of theca cells in a PCOS rat model: insights into follicular development. *J Ovarian Res* 18: 135 <https://doi.org/10.1186/s13048-025-01663-w>

(Manuscript received: 11th November, 2025; accepted: 22nd April, 2026).